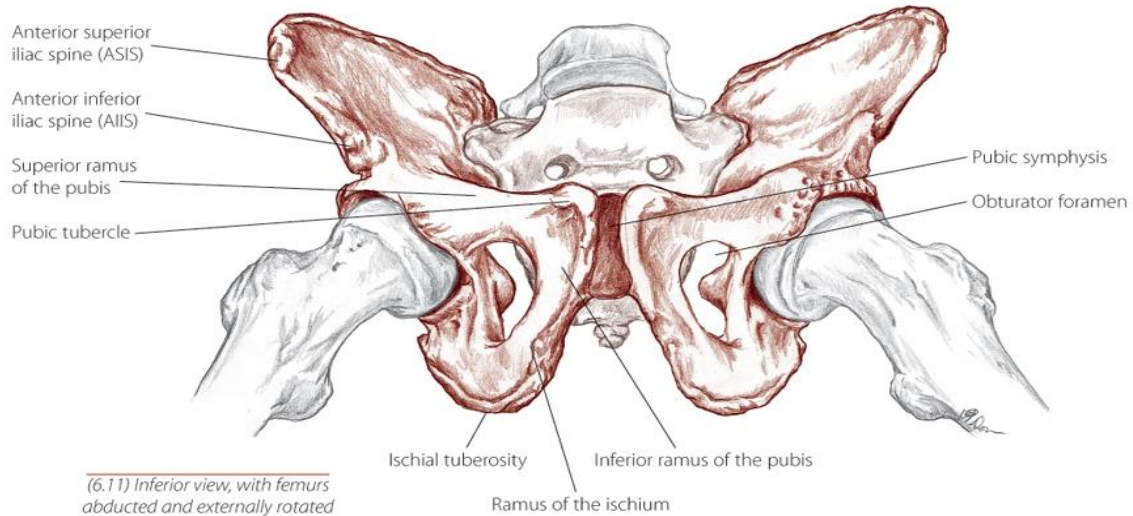


Illustration Credits:

All illustrations are taken from *The Trail Guide to the Human Body*,
Copyright 2006 by Books of Discovery.



ILLUSTRATIONS COPYRIGHT 2006 BOOKS OF DISCOVERY

TGB, p.278

The Pelvis

Three bones fuse to form each “innominate” (each half) of the pelvis:

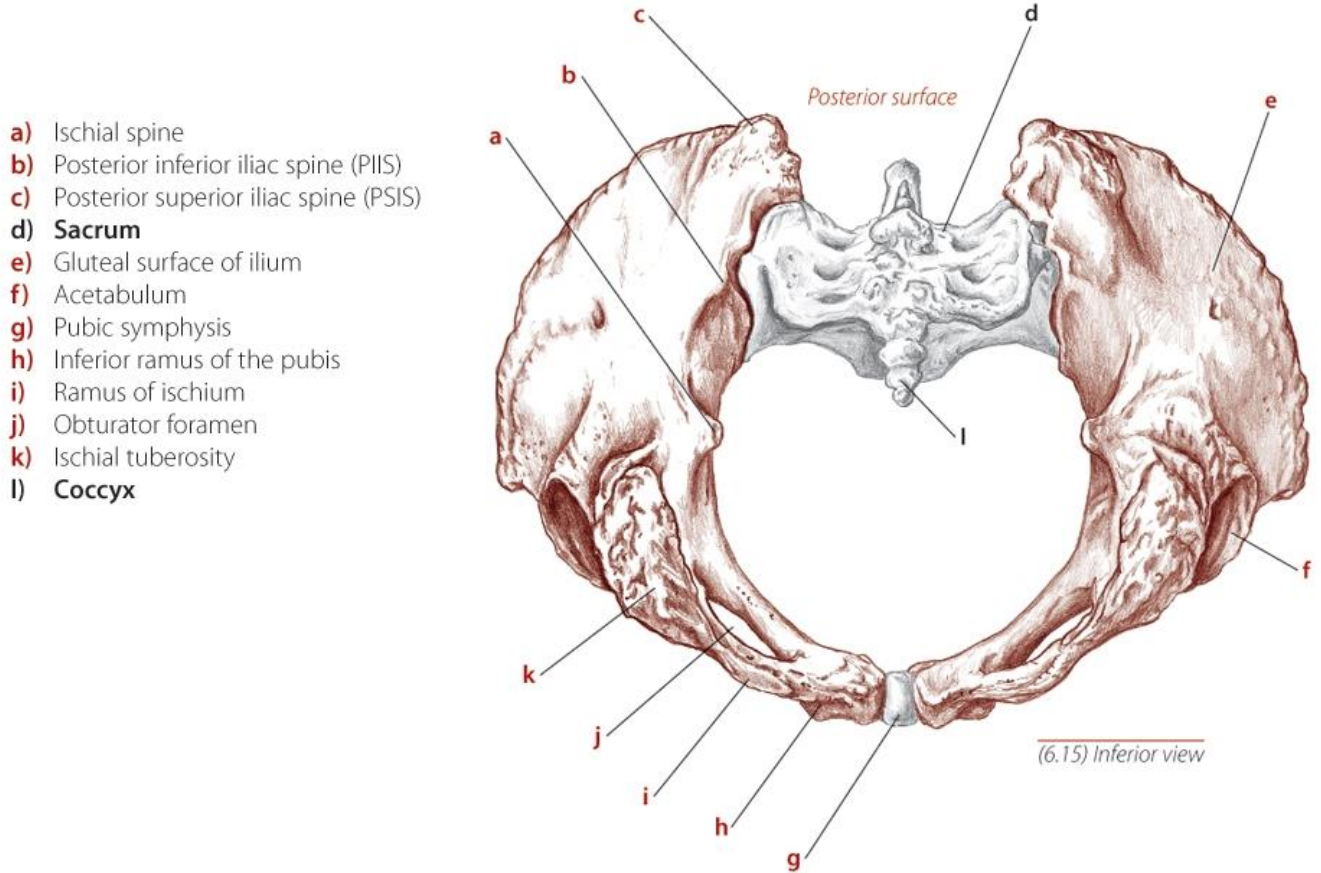
1. Ilium – large wing-like bone at the top
2. Ischium – pointy bone on which we sit
3. Pubis – straight bone at the bottom of the abdomen

The two innominates and the sacrum form the pelvis.

The sacrum is the shield-shaped bone at the back that has holes in it.

The two pubic bones meet in the front and are joined at the pubic joint.

The two innominates meet in the back at the sacrum and are joined by the sacroiliac joints.



The Pelvic Ring

You are looking from underneath.

d – Sacrum

e – Ilium

k – Ischium

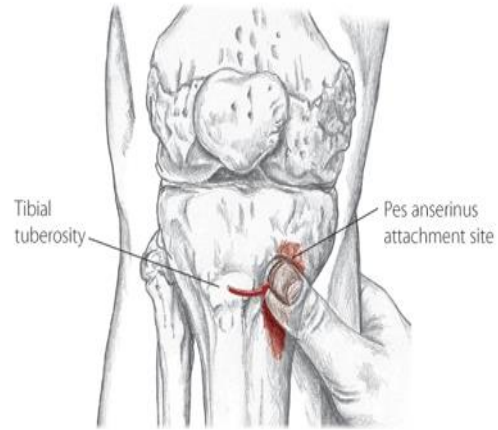
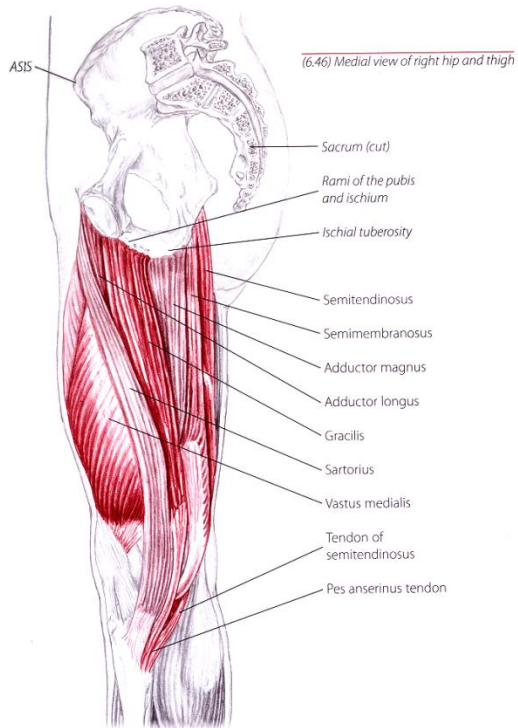
h – Pubic bone

g – Pubic joint

f – Acetabulum (hip socket)

b – close to left sacroiliac joint (the joint is the line between the sacrum and the ilium)

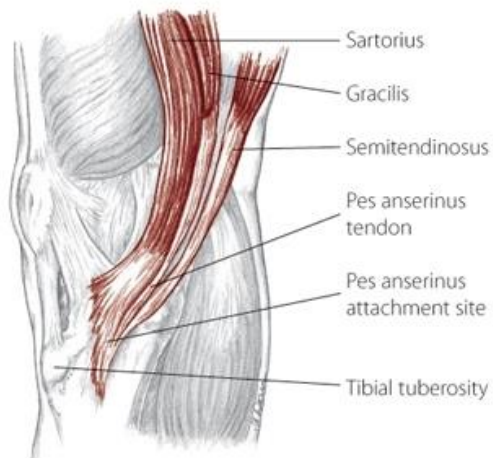
June 25 Radio Show Illustrations



(7.22) Anterior view of right knee

The thumb is on the pes anserinus.

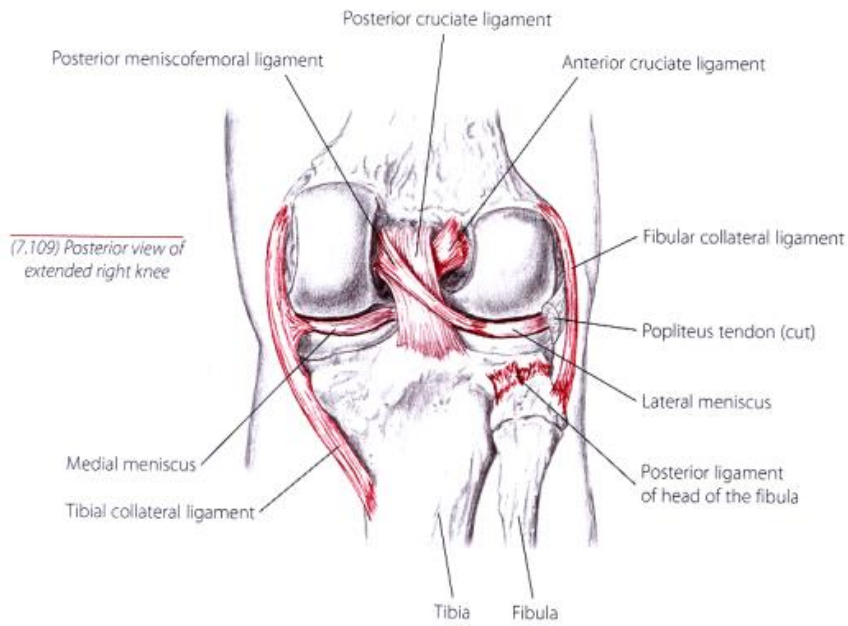
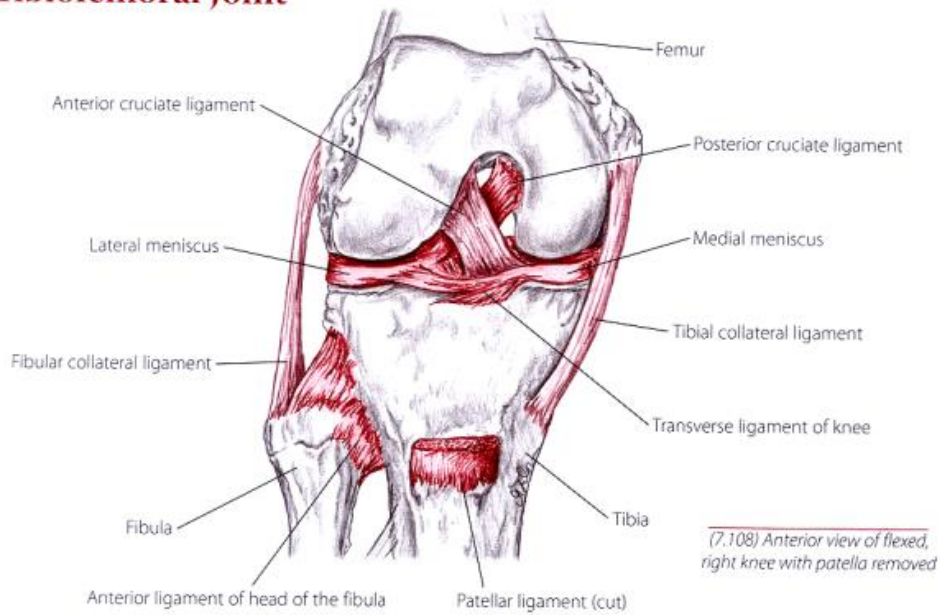
You are looking at the medial (inner) thigh.



(7.21) Medial view of right knee

Closeup of pes anserinus, where
Sartorius (from ilium)
Gracilis (from pubis)
Semitendinosus (from ischium)
meet – on the inside of the knee, below it

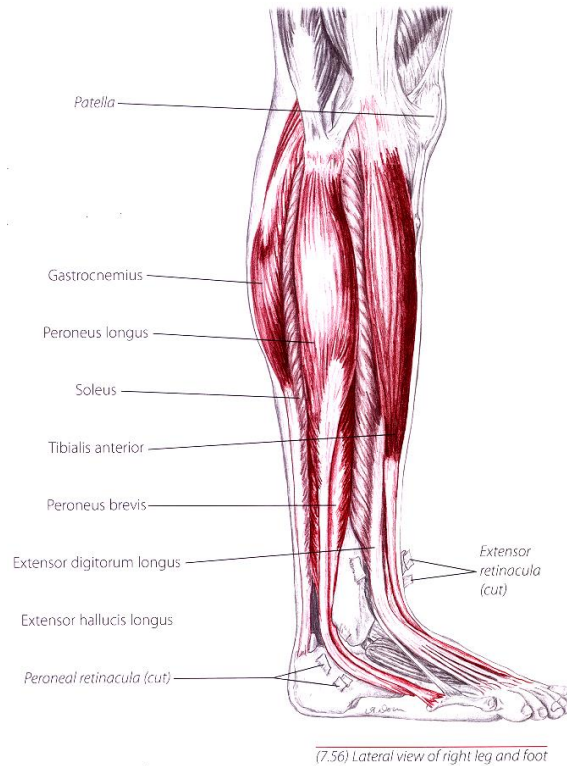
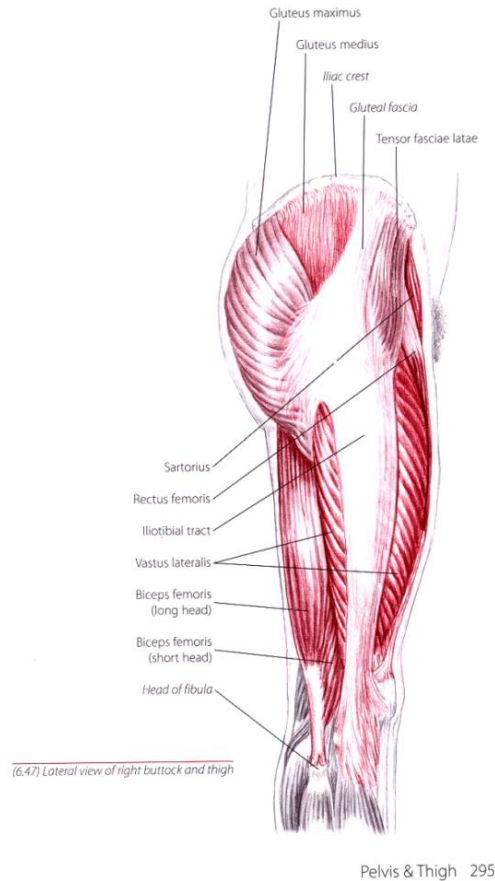
Tibiofemoral Joint



The Knee

The cruciate ligaments allow the femur and tibia to rotate.

June 25 Radio Show Illustrations



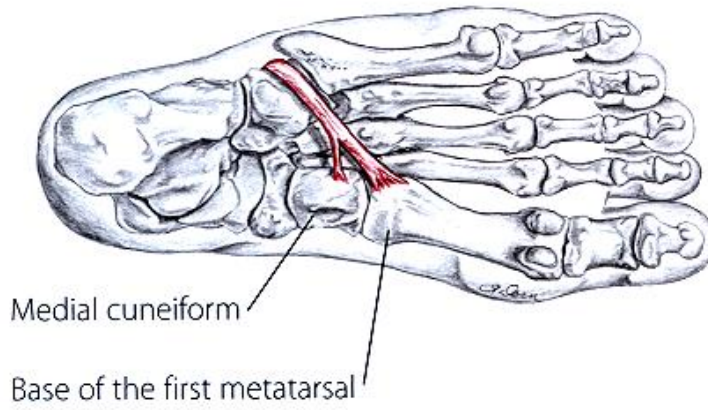
The Lower Leg

Anterior tibialis starts on the lateral side (outside) of the tibia, below the knee, where the IT Band attaches, and it ends under the first metatarsal.

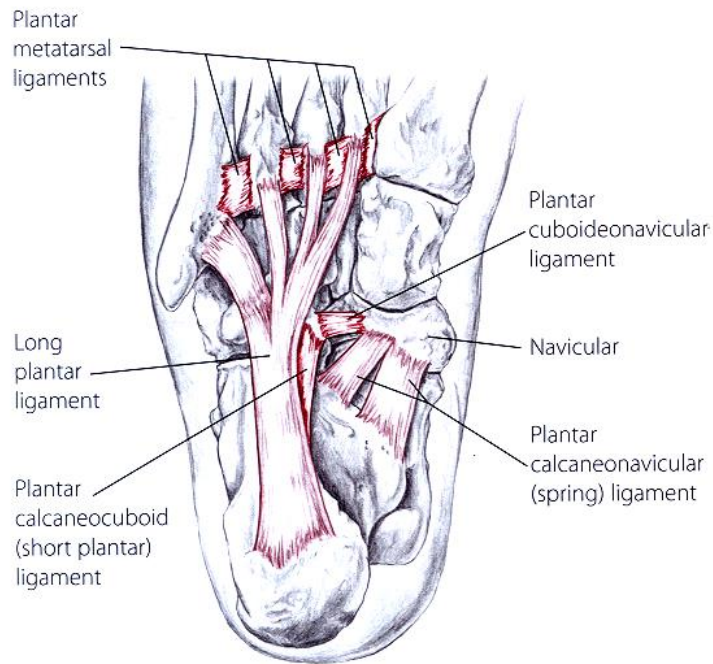
Peroneus longus starts at the proximal (upper) head of the fibula, where the biceps femoris (a hamstring) attaches, and it ends under the first metatarsal.

Peroneus brevis starts under the peroneus longus and ends at the fifth metatarsal.

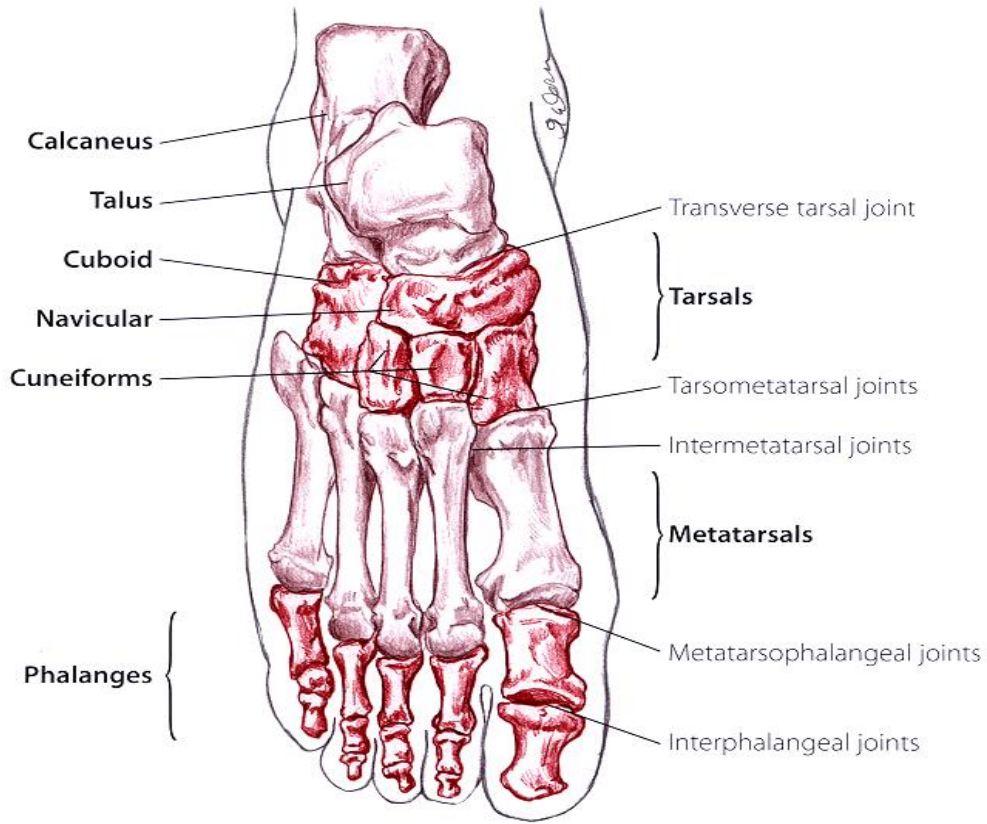
June 25 Radio Show Illustrations



(7.73) Plantar view of right foot showing peroneus longus tendon



(7.125) Plantar view of right foot showing ligaments of foot



(7.9) Dorsal view of right foot